

Post-Traumatic Bone Loss of the Femur Treated with Segmental Bone Allograft and Bone Morphogenetic Protein: A Case Report

P. D'Agostino, P. Stassen, Ch. Delloye

Cliniques du Sud Luxembourg, Arlon and Cliniques Universitaires Saint-Luc, Brussels, Belgium

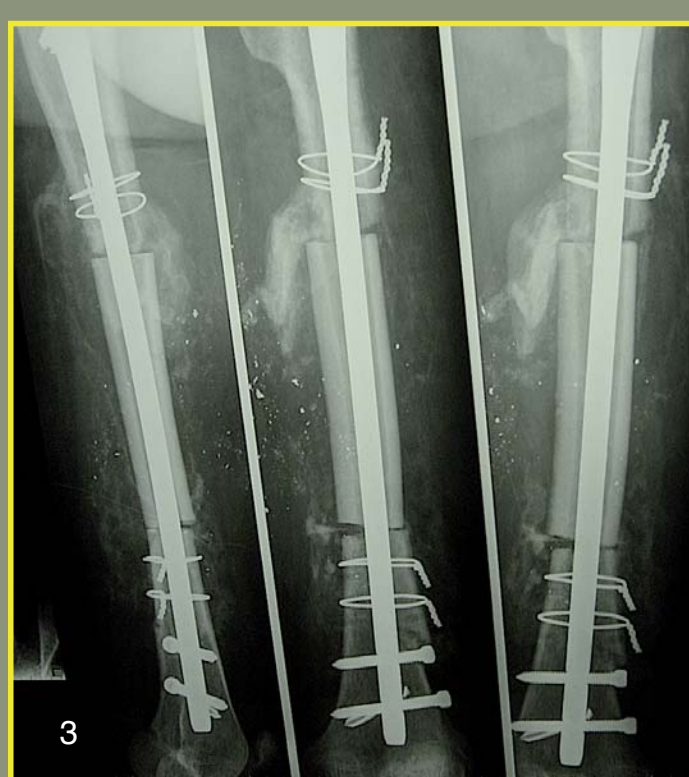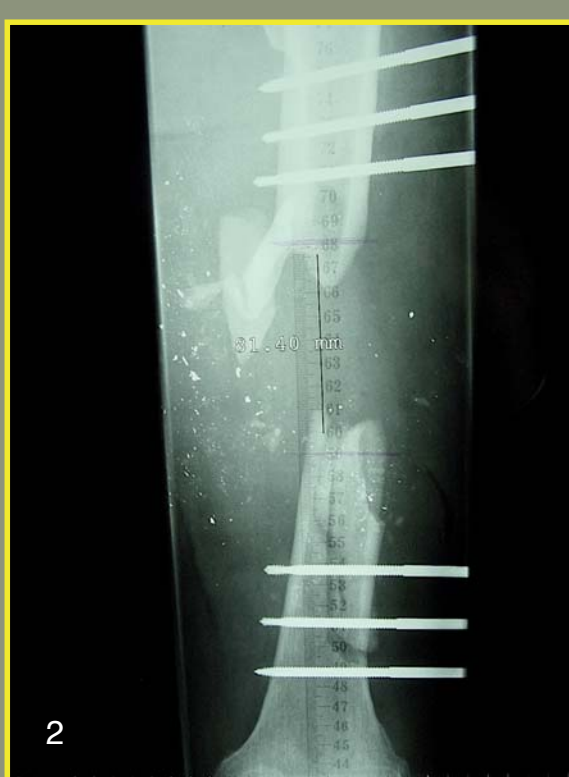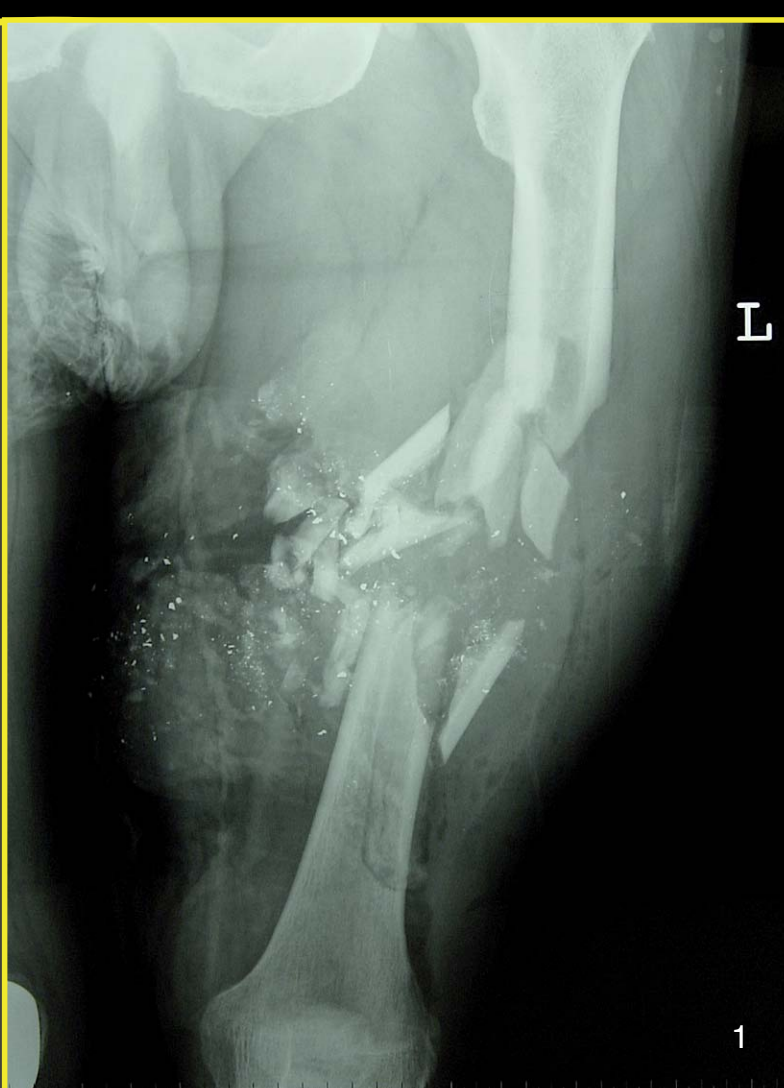INTRODUCTION

Bullet-caused wounds are extremely rare among our emergency cases. Between 2000 and 2005 : 7 cases of which 3 with airguns, suicides excluded. A severe open fracture require immediate débridement, pulse water lavage fixation and dressing. In some cases, the bone has been morcelised and cannot be fixed. If the resulting bone loss is major, it will be further treated with either a vascularised bone with or without a bone allograft, a bone transport or a two-stage reconstruction using bone cement first as a spacer followed by a bone grafting procedure.

We report the combined use of a bone allograft and osteoinductive growth factor to manage a large bone defect at the femur in a 57-year-old man after a hunting accident.

CASE REPORT

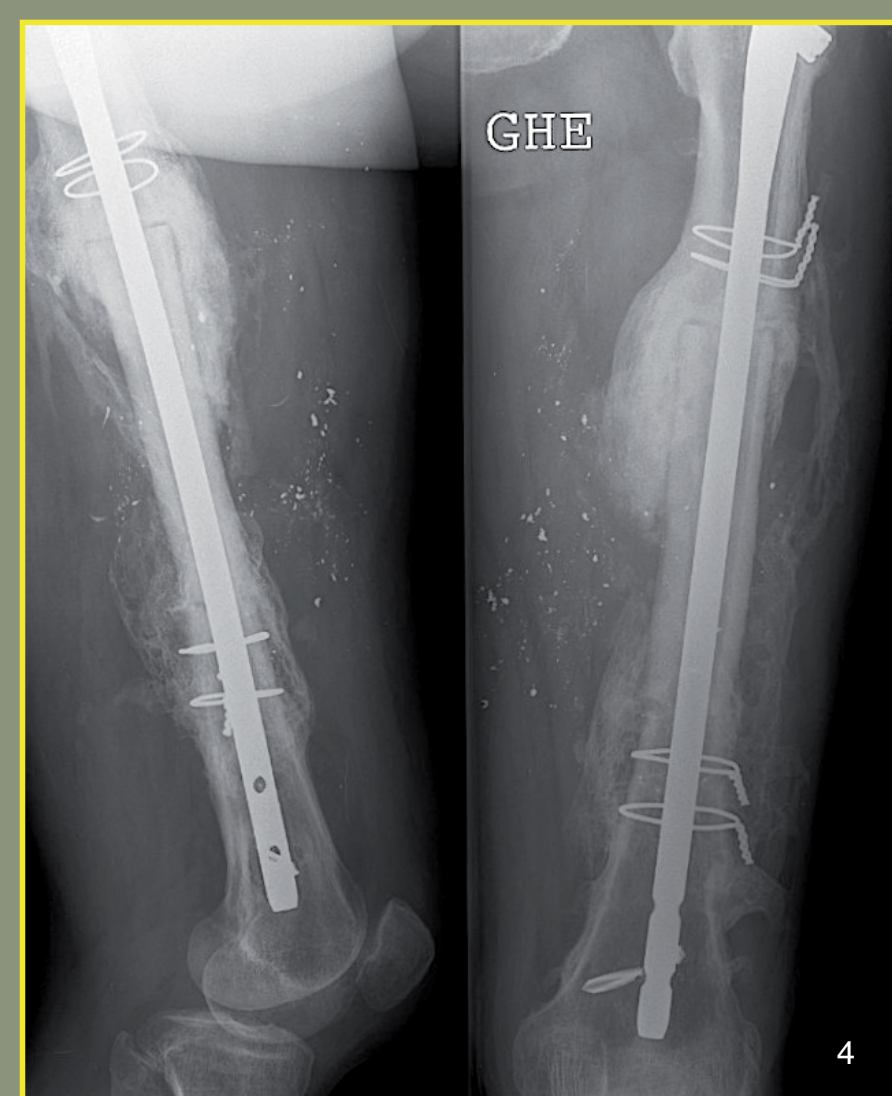
- Open fracture Gustillo IIIA
- Plurifragmentary
- Involve 1/3 of the femoral shaft
- Despite the effect of cavitation, no sign of vascular and neural injury



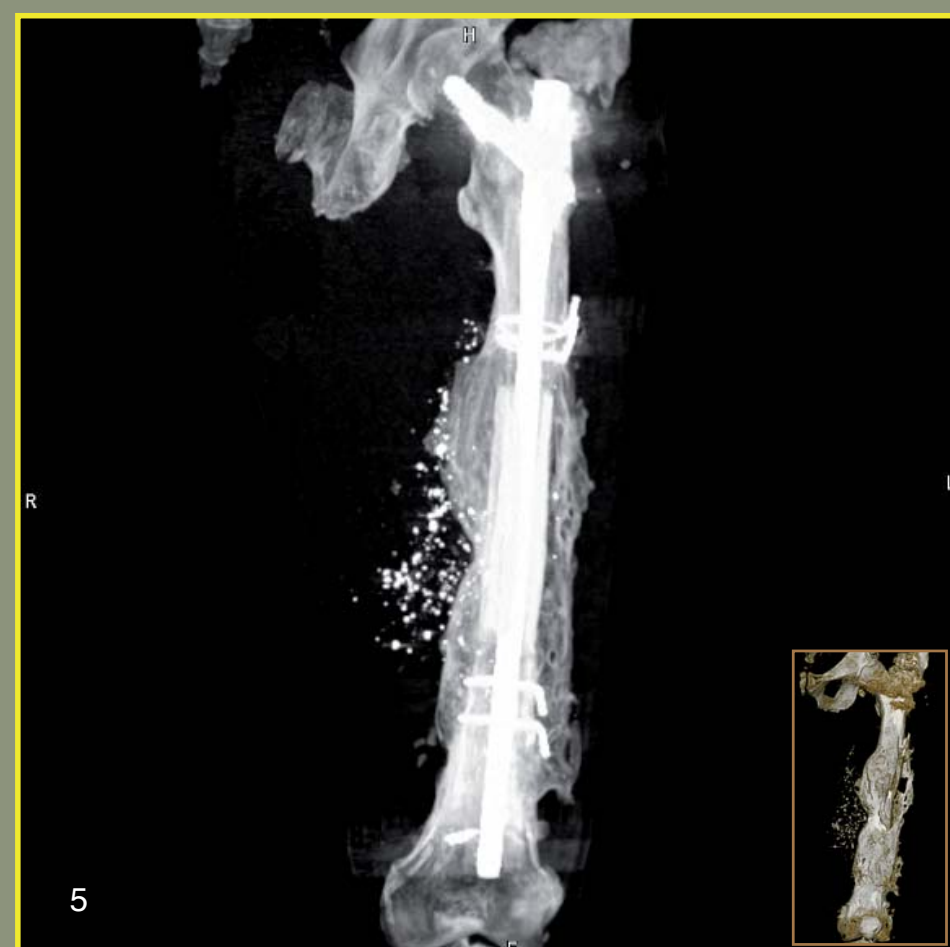- External fixator chosen as a first-line treatment
- Bone fragments removed and preserved at - 80°C
- Wound primarily closed and drained

- Reconstruction one month later
- Immediate reconstruction with a massive allograft
- 12-cm femoral bone allograft fixed by a long static locking gamma nail (Stryker, Brussels)
- One dose of rhBMP-7 (Osigraft TN, Stryker Biotec) applied at either side of the diaphyseal host-allograft

- First signs of healing on x-rays at 7 weeks
- Dynamisation of the nail performed at 3 months to fasten bone healing
- At 4 months, the allograft shows a good integration



- Frontal reconstruction showing a complete consolidation at 13 months
- Hypertrophic callus
- Heterotopic ossification in the muscles
- No axial deviation
- Leg length discrepancy minimal, 8 mm shortening



DISCUSSION

Post-traumatic defects are rare because there are now many options available for bone fixation. In this case, bone allografting was decided because it allowed a rapid weight bearing and in case of failure, it will not preclude the use of another option.

Bone allografting is associated with a high rate of non-union and fracture. In order to promote the bone healing at the anastomotic site, a recombinant human bone morphogenetic protein (rhBMP-7) was associated at either side of the bone allograft.

Conflicting results have been reported in the effectiveness of such molecules in the presence of allograft. Evidence of healing has been demonstrated in experimental conditions but not so far in human beings. Nevertheless, union was achieved at 13 months without bone autografting.